

## Crescentic IgA nephropathy following SARS-CoV-2 vaccination. Report of a case

### *Nefropatía extracapilar por IgA luego de la vacunación contra el SARS-CoV-2. Reporte de un caso*

Toprak Zeki <sup>1</sup>, Ersoy Yesil E. <sup>2</sup>, Zerenler Gursoy F. <sup>3</sup>, Demirbas M. B. <sup>4</sup>, Kayabaşı H. <sup>5</sup>, Sit D. <sup>6</sup>

#### RESUMEN

**Introducción:** Los estudios han demostrado que la frecuencia de insuficiencia renal aguda (IRA) aumenta en pacientes con COVID-19. Se ha informado que la necrosis tubular aguda es el daño más común en estos pacientes, probablemente debido a la alteración de la perfusión renal. Por otro lado, pueden estar involucrados diferentes procesos fisiopatológicos complejos, debido a los efectos directos de la infección viral sobre el sistema renina-angiotensina-aldosterona, la activación de la coagulopatía, la tormenta de citoquinas y la activación del sistema inmunológico. En estos pacientes se pueden observar muchas enfermedades glomerulares, como vasculitis asociada a anca, glomerulonefritis membranosa y nefropatía por IgA. **Caso clínico:** Presentamos un caso de nefropatía IgA extracapilar (NIgA) de nuevo diagnóstico tras una infección por SARS-CoV-2 y vacunación. Un hombre de 31 años sin antecedentes médicos presentó hematuria macroscópica 24 horas después de

la infección por SARS-CoV-2. La hematuria remitió espontáneamente en 3 días. Fue vacunado con dos dosis de CoronaVac (Sinovac) tres meses después de haber sido infectado por el SARS-CoV-2. Luego fue vacunado con la vacuna Pfizer-BioNTech COVID-19, un mes después de la segunda dosis de la vacuna CoronaVac (Sinovac). Presentó hematuria macroscópica y proteinuria no nefrótica 24 horas después de la primera dosis de la vacuna Pfizer-BioNTech COVID-19. Se realizó una biopsia renal que mostró NIgA extracapilar. Comenzó con metilprednisolona y bloqueador del receptor de angiotensina. Los pacientes que reciben vacunas basadas en ARNm demuestran anticuerpos contra el dominio de unión al receptor (RBD) de la proteína S1. De manera similar a la infección natural, debido a la fuerte estimulación de la respuesta inmunitaria de las vacunas basadas en ARNm en comparación con otras vacunas, los pacientes pueden producir anticuerpos de novo, lo que lleva a depósitos de complejos

#### Correspondencia:

Zeki Toprak

ORCID:

0000-0002-7411-3628

zktprk@gmail.com

#### Financiamiento:

Ninguno.

#### Conflicto de intereses:

Ninguno que declarar.

Recibido: 18-01-2022

Corregido: 27-01-2023

Aceptado: 08-05-2023

1) Department of Nephrology, University of Health Sciences, Umraniye Training and Research Hospital, Istanbul, Turkey.

2) Department of Nephrology, University of Health Sciences, Umraniye Training and Research Hospital, Istanbul, Turkey.

3) Health Sciences University, Umraniye training and research hospital clinic of Pathology Umraniye, Istanbul, Turkey.

4) Department of Nephrology, University of Health Sciences, Umraniye Training and Research Hospital, Istanbul, Turkey.

5) Department of Nephrology, University of Health Sciences, Umraniye Training and Research Hospital, Istanbul, Turkey.

6) Department of Nephrology, University of Health Sciences, Umraniye Training and Research Hospital, Istanbul, Turkey.

inmunitarios que contienen IgA. **Conclusiones:** Este caso destaca los efectos inmunológicos de las nuevas vacunas contra el SARS-CoV-2 basadas en ARNm. Los nefrólogos deben estar al tanto de la aparición de hematuria o proteinuria luego de la infección por SARS-CoV-2 o la vacuna contra el SARS CoV-2 basada en ARNm.

**PALABRAS CLAVE:** Lesión Renal Aguda; Covid-19; Nefropatía por IgA; Vacuna COVID-19

## ABSTRACT

**Introduction:** Studies have shown that the frequency of acute kidney injury (AKI) increases in patients with COVID-19. Acute tubular necrosis has been reported to be the most common damage in these patients, probably due to impaired renal perfusion. On the other hand, different complex pathophysiological processes may be involved due to viral infection's direct effects on the renin-angiotensin-aldosterone system, the activation of coagulopathy, the cytokine storm, and the activation of the immune system. Many glomerular diseases may be seen in these patients, like anca-associated vasculitis, membranous glomerulonephritis, and IgA nephropathy. **Clinical case:** We present a newly diagnosed crescentic IgA nephropathy (IgAN) case after a SARS-CoV-2 infection and vaccination. A 31-year-old man with no medical history presented with gross hematuria 24 hours after SARS-CoV-2 infection. Hematuria regressed spontaneously within three days. He was vaccinated with two doses of CoronaVac (Sinovac) three months after he had been infected by SARS-CoV-2. Then he was vaccinated with the Pfizer-BioNTech COVID-19 vaccine one month after the second dose of CoronaVac (Sinovac) vaccine. He presented with gross hematuria and subnephrotic proteinuria 24 hours after the first dose of the Pfizer-BioNTech COVID-19 vaccine. A kidney biopsy was performed and showed crescentic IgA nephropathy (IgAN). He was started on methylprednisolone and angiotensin receptor blocker. Patients who receive mRNA-based vaccines demonstrate robust antibody production against the receptor-binding domain (RBD) of the S1 protein. Similar to natural infection, due to the intense stimulation of immune response from mRNA-based vaccines compared to other vaccines, the patients may produce de novo antibodies, leading to IgA-containing immune-complex

deposits. **Conclusions:** This case highlights the immunological effects of the novel mRNA-based SARS-CoV-2 vaccines. Nephrologists should be aware of new-onset hematuria or proteinuria after SARS-CoV-2 infection or mRNA-based SARS-CoV-2 vaccine.

**KEYWORDS:** Acute Kidney Injury; Covid-19; IgA Nephropathy; COVID-19 vaccin.

## INTRODUCTION

At the end of 2019, a novel coronavirus was identified as the cause of a cluster of pneumonia cases in China; the infection rapidly spread worldwide, resulting in a global pandemic <sup>(1)</sup>. Coronavirus disease 2019 (COVID-19) is thought to cause acute kidney injury (AKI) by various mechanisms. The proposed mechanisms of kidney injury are numerous and range from a direct viral infection that affects the renin-angiotensin-aldosterone system to hemodynamic instability, the activation of coagulopathy, cytokine storm, and the activation of the immune system <sup>(2,3)</sup>. IgA nephropathy (IgAN) is the most common lesion found to cause primary glomerulonephritis throughout most developed countries of the world. IgAN is typically triggered by upper respiratory infections, and relapse of IgAN has been reported in patients receiving vaccinations <sup>(4-8)</sup>. Here, we present a case of newly diagnosed crescentic IgAN after SARS-CoV-2 infection and mRNA-based SARS-CoV-2 vaccine.

## CASE REPORT

A 31-year-old man with no medical history presented with gross hematuria 24 hours after SARS-CoV-2 infection. He reported no personal history of kidney disease, including IgAN. The diagnosis of COVID-19 was made primarily by direct detection of viral reverse-transcription polymerase chain reaction (RT-PCR) from the upper respiratory tract. Chest computed tomography findings were consistent with SARS-CoV-2 infection. He did not have hospitalization during SARS-CoV-2 infection. He was treated with favipiravir and paracetamol. He did not have a urinalysis when he had gross hematuria. Serum creatinine was 0,93 mg/dL (Ref: 0.76-1.27 mg/dL), and the estimated glomerular filtration rate was 109 ml/min/1.73 m<sup>2</sup>. Hematuria had been resolved

spontaneously within three days. He was not referred to nephrology during the gross hematuria attack. However, due to the development of hematuria after the viral infection, its spontaneous recovery, and the absence of a kidney stone story, we think that he had an attack of IgAN even though he did not have a urine test or histopathological evidence. He had been vaccinated with two doses of CoronaVac (Sinovac) three months after the SARS-CoV-2 infection, and he did not describe a hematuria attack after the CoronaVac (Sinovac) vaccine. He had been vaccinated with the Pfizer-BioNTech COVID-19 vaccine one month after the second dose of CoronaVac (Sinovac) vaccine, and gross hematuria occurred 24 hours after the Pfizer-BioNTech COVID-19 vaccine. He was referred to nephrology for consultation. The patient had no history of renal disease, and there was no hematuria in the past urine analysis. Physical examination was normal, and blood pressure was 123/75 mm Hg. He did not have lower extremity edema, rash, lymphadenopathy, or throat erythema. Serum creatinine was 1.15 mg/dL (Ref:

0.76-1.27 mg/dL), and the estimated glomerular filtration rate was 84 ml/min/1.73 m<sup>2</sup>. A urinalysis showed 3+ protein (ref: negative), 242 red blood cells per high-power field (ref: 0-3), 13 white blood cells per high-power field (ref: 0-4), and 3+ blood (ref: negative). The random urine protein-creatinine ratio was 0.67 g/g (ref: 0-0.2 g/g), estimating 24-hour urine protein excretion of 670 mg. 24-hour urine protein was 1083 mg/day. Kidney ultrasound showed mildly increased echogenicity of average size and cortical thickness. Additional serological work-up for glomerulonephritis was negative, including hepatitis B antigen, anti-hepatitis C antibody, anti-HIV (Human immunodeficiency virus) antibody, and antinuclear and antineutrophil cytoplasmic antibodies. Erythrocyte sedimentation rate, Rheumatoid factor, and C-reactive protein levels were normal. Complements C3 (1.56, ref: 0.9-1.8 g/L) and C4 (0.4, ref: 0.1-0.4 g/L) were normal. Creatinine phosphokinase was 109 U/L (ref: 30-200 U/L), and Immunoglobulin A level was normal. The patient's laboratory results, timeline of infection, and vaccinations are shown in **Table 1**.

**Table 1:** Timeline of patient's infection and vaccinations

	SARS-CoV-2 infection March 2 - 2021	Coronavac vaccine June 15 - 2021	Pfizer biontech vaccine July 24 - 2021	After IgAN treatment October 11 - 2021
Blood urea nitrogen (mg/dl)	29,96	-	19,9	33,7
Serum creatinine (mg/dl)	0,94	-	1,15	0,81
C reactive protein (mg/L)	2,2	-	9,55	7,26
Glomerular filtration rate (ml/mn/1,73 m <sup>2</sup> )	108,36	-	84,32	118,43
Protein (mg/24 hours urine)	-	-	1083,6	274,82
Urinalysis	-	-		
Red blood cell	-	-	242	4
Protein	-	-	++	-
White blood cell	-	-	13	20

Given the unclear diagnosis, an ultrasound-guided percutaneous renal biopsy was performed. Light microscopy revealed 77 glomeruli, most of which had a mild mesangial expansion, hypercellularity with endocapillary hypercellularity,

and adhesion of a capillary loop to the Bowman capsule (**Figure 1**), 1 of which showed global sclerosis, 1 of which showed segmental sclerosis.

Mild tubular atrophy and interstitial fibrosis are present. H&E x 100.

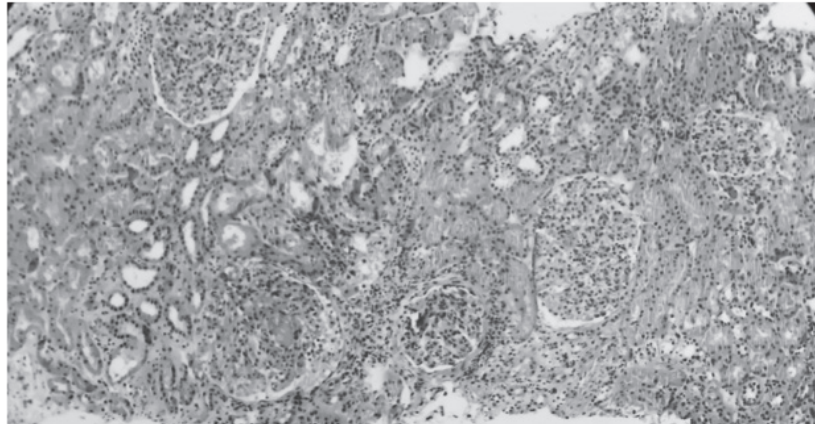
4 of which showed cellular crescent (**Figure 2**), 1 of which showed fibrous crescent (7.7%), 2 of which showed fibrinoid necrosis.

While a cellular crescent is observed in the left

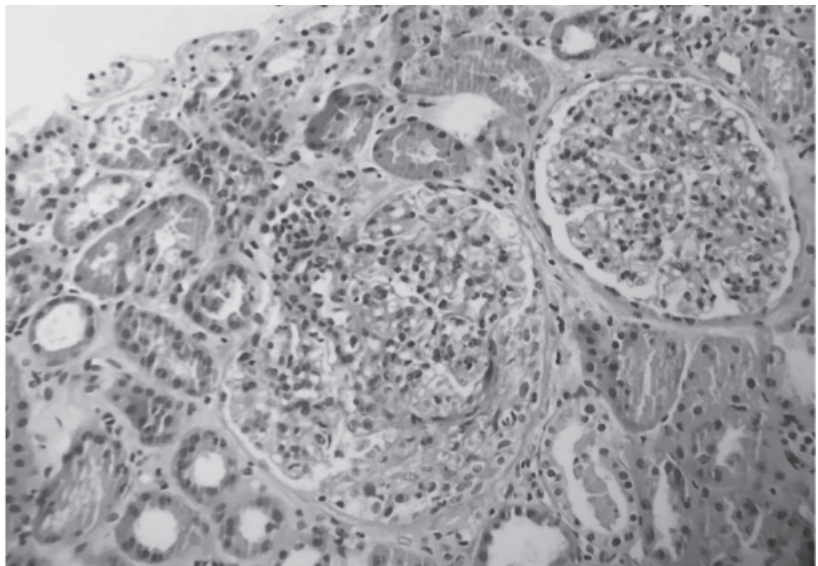
glomerulus, an increase in mesangial cellularity is observed in the other glomerulus. H&E x200.

Immunofluorescence revealed 3+ diffuse granular mesangial staining for IgA (**Figure 3**).

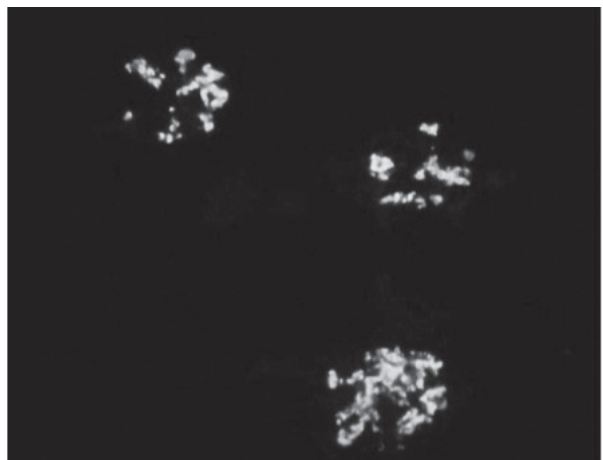
**Figure 1**



**Figure 2**



**Figure 3:** Mesangial accumulation in glomeruli with IgA in direct immunofluorescence examination x40



Staining was positive for C3 and negative for IgG and other immunoglobulins and complement antibodies. Mild tubular atrophy and interstitial fibrosis were observed. Erythrocyte clumps, hemoglobin casts, and hyaline casts were detected in some tubular lumens. Pathologic features were consistent with IgAN with Oxford MEST-C classification as M1-E0-S1-T1-C1, and his risk of a 50% decline in estimated glomerular filtration rate or progression to kidney failure within five years was approximately 9.75%, as per a recent risk prediction model by the International IgA Nephropathy Network. He started on Ramipril 10 mg daily, 1 gr pulse Methylprednisolone for one day, following 1mg/kg/day, and fish oil, which was well tolerated. After eight weeks of therapy, the urine protein-creatinine ratio improved to 0.27 g/g, and creatinine remained stable at 0.83 mg/dL.

## DISCUSSION

Here we present a patient with probable de novo crescentic IgAN associated with COVID-19 infection. Our patient's Pfizer-BioNTech COVID-19 vaccine and COVID-19 infection triggered a gross hematuria attack.

IgAN is the most common lesion found to cause primary glomerulonephritis throughout most developed countries. Patients may present at any age, but there is a peak incidence in the second and third decades<sup>(9)</sup>. Upper respiratory tract infections often precede the onset or exacerbation of the IgAN. Various immune triggers for IgAN have been published, including staphylococcal infection, vaccination, and viral infection<sup>(4-8)</sup>. Viral infections contribute to the multihit hypothesis of IgAN and trigger a cascade of events, including an increase in circulating galactose-deficient IgA1 (gd-IgA1) antibodies, development of autoreactive antibodies to gd-IgA1, and formation of immune complexes that deposit in various tissues, including the kidney, triggering an inflammatory response<sup>(10)</sup>. IgAN is an immune-complex disease characterized by mesangial IgA1 deposition with or without concurrent IgG and C3 deposits.

Renal manifestations of SARS-CoV-2 infection encompass the spectrum of kidney injury, including increased serum creatinine levels and asymptomatic urinary abnormalities<sup>(11)</sup>. In patients admitted to the hospital with COVID-19, asymptomatic urinary abnormalities like hematuria and proteinuria or AKI are significantly

associated with increased mortality<sup>(12)</sup>. Renal biopsy series have been reported reviewing kidney pathology from patients with COVID-19. In 26 biopsies, Su H et al. reported no samples demonstrated hypercellular or inflammatory glomerular lesions, or crescents, despite including patients with hematuria and proteinuria. The most common pathological finding reported was acute tubular injury, which was suggested to be direct viral effects in the proximal tubule epithelium<sup>(13)</sup>.

Our patient presented with gross hematuria 24 hours after SARS-CoV-2 infection and the Pfizer-BioNTech COVID-19 vaccine. While COVID-19-related AKI is seen in relatively severe hospitalized patients, our patient was managed in an outpatient clinic given the mild COVID-19 presentation during the SARS-CoV-2 infection. Gross hematuria regressed spontaneously within three days after the SARS-CoV-2 infection. He had been vaccinated with two doses of CoronaVac (Sinovac) three months after SARS-CoV-2 infection. Furthermore, he had been vaccinated with the Pfizer-BioNTech COVID-19 vaccine one month after the second dose of CoronaVac (Sinovac) vaccine.

Ran E et al. reported a case of crescentic IgAN following the CoronaVac vaccine<sup>(14)</sup>. However, our patient did not describe a hematuria attack after the CoronaVac (Sinovac) vaccine doses. However, he presented with gross hematuria and subnephrotic proteinuria 24 hours after the first dose of the Pfizer-BioNTech COVID-19 vaccine. People who receive mRNA-based vaccines demonstrate robust antibodies against the receptor-binding domain (RBD) of the S1 protein. Similar to natural infection, due to the powerful stimulation of immune response from mRNA-based vaccines compared to other vaccines, the patients may produce de novo antibodies, leading to IgA-containing immune-complex deposits in the kidney. Besides COVID-19 vaccines, influenza and the recombinant zoster vaccine may cause hematuria and flare-up IgA nephropathy<sup>(15)</sup>. In addition, other vaccines, such as hepatitis B, measles, and pneumococcus, have been linked to renal pathologies like nephrotic syndromes<sup>(16)</sup>. Nevertheless, according to some recent studies, developing glomerulonephritis after vaccination against SARS-CoV-2 may be a rare adverse event. They claimed a temporal association was found for IgAN and minimal change disease, but causality

was not firmly established<sup>(17)</sup>.

This case highlights the immunological effects of the novel mRNA-based SARS-CoV-2 vaccines. Nephrologists should be aware of new-onset hematuria or proteinuria observed after SARS-CoV-2 infection or mRNA-based SARS-CoV-2 vaccine.

## BIBLIOGRAPHY

- 1) Ghebreyesus TA, *Organization WHOJWH*. Director-general's remarks at the media briefing on 2019-nCoV on 11 February 2020. 2020;11.
- 2) Faour WH, Choib A, Issa E, Choueiry FE, Shbaklo K, Alhadj M, et al. . *Mechanisms of COVID-19-induced kidney injury and current pharmacotherapies*. 2021;1-18.
- 3) Benedetti C, Waldman M, Zaza G, Riella LV, Cravedi PJFim. *COVID-19 and the kidneys: an update*. 2020;7.
- 4) Koyama A, Sharmin S, Sakurai H, Shimizu Y, Hirayama K, Usui J, et al. . *Staphylococcus aureus cell envelope antigen is a new candidate for the induction of IgA nephropathy*. 2004;66(1):121-32.
- 5) Suzuki S, Sato H, Tsukada H, Arakawa M, Nakatomi YJTL. *Haemophilus parainfluenzae antigen and antibody in renal biopsy samples and serum of patients with IgA nephropathy*. 1994;343(8888):12-6.
- 6) Alonso M, Villanego F, Segurado Ó, Vigara LA, Orellana C, García T, et al. . *De novo IgA nephropathy in a kidney transplant recipient after SARS-CoV-2 vaccination*. 2021.
- 7) Watanabe TJPN. *Henoch-Schönlein purpura following influenza vaccinations during the pandemic of influenza A (H1N1)*. 2011;26(5):795-8.
- 8) García AR, Gallego E, Navarro JJNpodISEN. *Macroscopic hematuria after immunization with tetanus toxoid in a patient with IgA nephropathy*. 2002;22(2):210-1.
- 9) Yeo SC, Goh SM, Barratt JJN. *Is immunoglobulin A nephropathy different in different ethnic populations?* 2019;24(9):885-95.
- 10) Placzek WJ, Yanagawa H, Makita Y, Renfrow MB, Julian BA, Rizk DV, et al. . *Serum galactose-deficient-IgA1 and IgG autoantibodies correlate in patients with IgA nephropathy*. 2018;13(1): e0190967.
- 11) Sundaram S, Soni M, Annigeri RJD, Research MSC, Reviews. *Urine abnormalities predict acute kidney injury in COVID-19 patients: An analysis of 110 cases in Chennai, South India*. 2021;15(1):187-91.
- 12) Kanbay M, Medetalibeyoglu A, Kanbay A, Cevik E, Tanriover C, Baygul A, et al. . *Acute kidney injury in hospitalized COVID-19 patients*. *International urology and nephrology*. 2021;1-8.
- 13) Su H, Yang M, Wan C, Yi LX, Tang F, Zhu HY, et al. . *Renal histopathological analysis of 26 postmortem findings of patients with COVID-19 in China*. *Kidney international*. 2020;98(1):219-27.
- 14) Ran E, Wang M, Wang Y, Liu R, Yi Y, Liu Y. *New on set crescent Ig A nephropathy following the CoronaVac vaccine*. 2022. *Medicine*; 101:33.
- 15) Kavukcu S, Soylu A, Sarioglu S et al. . *IgA nephropathy in mice following repeated administration of conjugated haemophilus influenza type B vaccine*. Takai. *J Exp Clin Med*. 1997; 22:167-74.
- 16) Rahim SEG, Lin JT, Wang JC. *A case of gross hematuria and IgA nephropathy flare up following SARS-Cov-2 vaccination*. *Kidney Int*. 2021; 100:238.
- 17) Waldman M, Sinaii N, Lerma EV, et al. . *COVID-19 Vaccination and New Onset Glomerular Disease: Results from the IRocGN2 International Registry*. *Kidney360*. 2023;4(3):349-362.