

Influence of SARS-CoV-2 on the Progression of Infection to Tuberculous Disease. Presentation of 3 Cases

Influencia del SARS-CoV-2 en la progresión de infección a enfermedad tuberculosa. A propósito de 3 casos

Ubal, Leonardo German^{1,2}; Acosta, María Alejandra¹; Oviedo, Eduardo Enrique¹; Fernández, Rocío Guadalupe¹; Appiolaza, Alejandra¹; Kevorkof, Gregorio Varujan^{1,2}

Received: 07/29/2022

Accepted: 11/30/2022

Correspondence

Leonardo Ubal

e-mail: leoub6@hotmail.com

ABSTRACT

Introduction: SARS-CoV-2 is likely to favor the transition from infection to tuberculous disease. Although information is limited, there is progress in understanding the interaction between COVID-19 and tuberculosis. New investigations yielded unexpected similarities in the pathogenesis and evolution of the coinfection. Prolonged lymphopenia, hyperinflammation, lung tissue injury, and imbalance in CD4+ T-cell subsets associated with COVID-19 could propagate *M. tuberculosis* infection and disease progression.

Case reports: we present three young patients, without comorbidities, with risk factors for latent tuberculous infection, diagnosed with pulmonary tuberculosis post mild COVID-19, with symptomatic treatment (not corticosteroids).

Discussion: these cases raise the probable impact of SARS-CoV-2 in the transition from latent tuberculous infection to disease, excluding the already proven influence of corticosteroids and severe forms of COVID-19. There is increasing evidence to support this idea.

Key words: COVID-19; SARS-CoV-2; tuberculosis

RESUMEN

Introducción: es probable que SARS-CoV-2 favorezca el paso de infección a enfermedad tuberculosa. Si bien la información es limitada, hay avances en la comprensión de la interacción COVID-19 y Tuberculosis. Nuevas investigaciones arrojaron similitudes inesperadas en la patogenia y evolución de la coinfección. Linfopenia prolongada, hiperinflamación, lesión del tejido pulmonar y desequilibrio en los subconjuntos de células T CD4+ asociados con COVID-19, podrían propagar la infección por *M. tuberculosis* y progresión de la enfermedad.

Casos clínicos: presentamos tres pacientes jóvenes, sin comorbilidades, con factores de riesgo para Infección Tuberculosa Latente, diagnosticados de Tuberculosis pulmonar posterior cursado COVID-19 leve, de tratamiento sintomático (no corticoideo).

Discusión: estos casos plantean el probable impacto del SARS-CoV-2 en el paso de Infección Tuberculosa Latente a enfermedad, excluyendo la ya demostrada influencia de los corticoides y formas graves de COVID-19. Existe cada vez más evidencia que refuerza esta idea.

Palabras clave: COVID-19; SARS-CoV-2; tuberculosis

INTRODUCTION

In December 2019, the world faced a new coronavirus (SARS-CoV-2) which caused COVID-19.¹ In 2020, as a result of the pandemic, the tuberculosis (TB) control services were interrupted. The World Health Organization (WHO) recorded a reduction in the global number of patients diagnosed and treated for TB and an increase in the number of deaths, for the first time in decades.^{2,3}

COVID-19 can affect people infected or ill with TB before, during or after being cured, facilitating in some cases the transition from latent tuberculous infection (LTBI) to disease, and also increasing the possibility of making TB evolution more severe due to a higher extension of pulmonary lesions.³⁻⁵

It has been proven that people with TB have higher risk of death from COVID-19³ and that the use of corticosteroids both for the acute phase and for post COVID-19 organizing pneumonia can lead to TB reactivation.^{1,2,5} It has also been observed that the “unfavorable” evolution of COVID-19 implies a higher risk of progression from LTBI to active TB.⁶

Even though information is still limited, there is growing understanding of the interaction of both diseases, and COVID-19 will probably favor the transition from infection to tuberculous disease, regardless of the severity of its course.⁷

New research on the molecular and cellular mechanisms of *M. tuberculosis* and SARS-CoV-2 infections have yielded unexpected similarities regarding the pathogenesis and evolution of the coinfection. Long-term lymphopenia, hyperinflammation, lung tissue injury, and imbalance in CD4+ T-cell subsets associated with COVID-19 could propagate the *M. tuberculosis* infection and disease progression.^{1,8}

The co-existence of TB and COVID-19 is presented in Argentina with undetermined values, and a risk which we can assume has increased.^{2,9,10}

We present three case reports of young patients without relevant comorbidities, with risk factors for LTBI (healthcare personnel, family contact) who were diagnosed with pulmonary TB post mild COVID-19 infection, with outpatient symptomatic treatment (not corticosteroids).

CASE REPORTS

Case N° 1: 25-year-old female, resident doctor. Diagnosis of prolactinoma, medicated with cabergoline. Claims she doesn't have any history of allergies, surgeries, or use of toxic substances. No family members or cohabitants with history of TB. Complete vaccination scheme for SARS-CoV-2; BCG (bacille Calmette-Guerin) administered when the patient was a child. She had COVID-19 in May 2021, with mild symptoms of the upper airway (UAW), cephalaea, dry cough, anosmia and ageusia; no pulmonary involvement.

After having COVID-19, she still had dry cough, initially associated with post-viral sequelae. In July 2021, she started to have episodes of night sweating, weight loss and occasional sibilance, so she started to use supplementary methods, and the chest X-ray showed cavitary infiltrate in right upper lobe (RUL), with suspicion of pulmonary TB. Respiratory physical examination: crepitant rales in the upper area of the right field and isolated sibilance at auscultation.

August 2021: chest CAT (computed axial tomography) shows condensation with alveolar aspect at the posterior segment of the RUL, identifying small images compatible with caves, the biggest being 8 mm (Figure 1). Laboratory: high erythrocyte sedimentation rate, negative viral serology. Diagnostic fibrobronchoscopy (FBC) performed with lavage and bronchial biopsy with 3 and 8 BAAR (acid-alcohol-resistant bacillus)/field, respectively, and positive cultures. Patient begins treatment for Category 1 pulmonary TB (unilateral with cave), first phase 2HRZE (isoniazid, H; rifampicin, R;

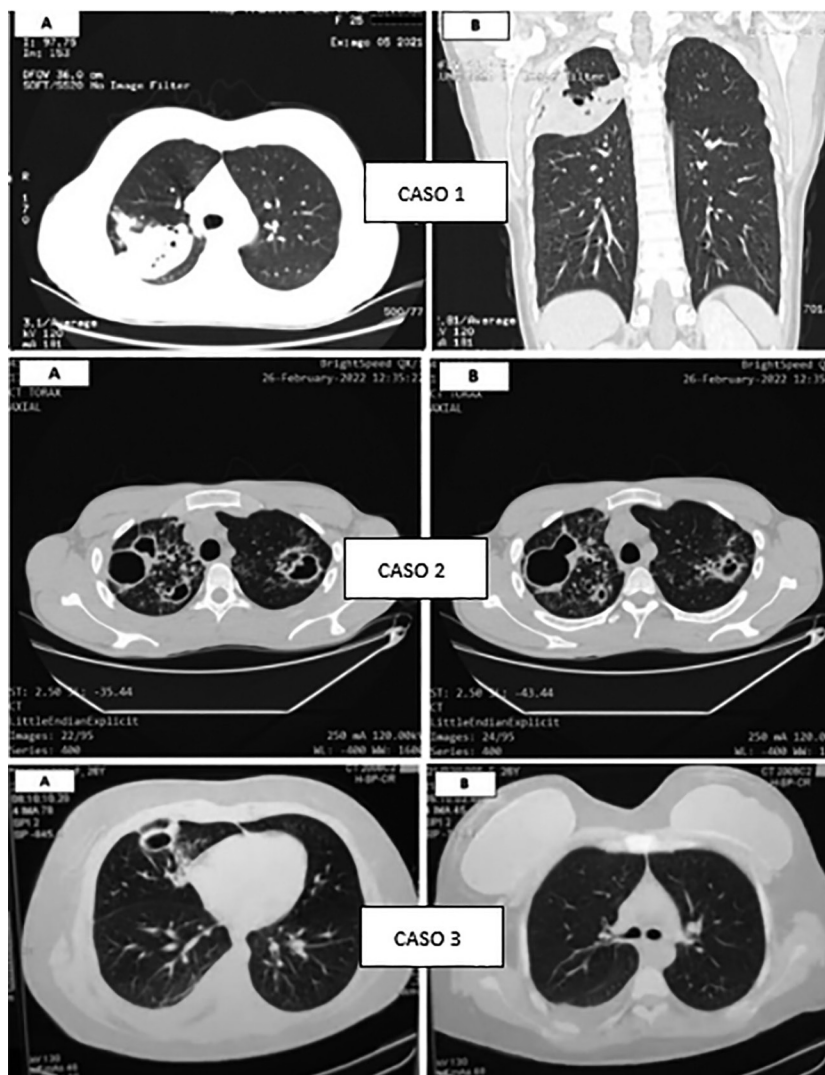


Figure 1. Chest tomography images (lung windows). Case 1: condensation with alveolar aspect at RUL with small cave. Case 2: multiple caves of thick walls in upper fields, associated with large tree-in-bud pattern. Case 3: subsegmental linear atelectasis at middle lobe, caves with thick walls and mild pleural effusion.

pyrazinamide, Z, and ethambutol, E), and second phase 4HR (isoniazid, H; rifampicin, R), with favorable response.

Case N° 2: 22-year-old male who works at an energy cooperative. No history of diseases, allergies or use of toxic substances. Cohabits with mother, father, and 3 siblings. History of pulmonary TB in the family: the patient's mother in 2014 (full treatment), and also the patient's paternal grandfather and uncle. Complete vaccination scheme for SARS-CoV-2; BCG administered when the patient was a child. He had COVID-19 in April 2021, without respiratory symptoms.

Since May 2021, after COVID-19, he's been having cough and mucous expectoration, occasionally mucopurulent (not hemoptoic), dyspnea on exertion, and weight loss. Makes several medical consultations and uses different antibiotic regimens without symptom improvement. Respiratory physical examination: rhonchus and movement of secretions with coughing.

February/March 2022: chest CAT shows multiple caves of thick walls predominant in upper fields, associated with large tree-in-bud pattern and ill-defined opacities with consolidative aspect (Figure 1). Laboratory: high erythrocyte sedimen-

tation rate, negative viral serology. Sputum for Koch with >10 BAAR/field in two samples. Patient begins treatment for Category 1 pulmonary TB (bilateral with cave), first phase 2HRZE and second phase 4HR.

Case N° 3: 26-year-old female, resident doctor. History of obesity class II (BMI: 35). No history of allergies, surgeries, or use of toxic substances. No family members or cohabitants with history of TB. Complete vaccination scheme for SARS-CoV-2; BCG administered when the patient was a child. She had COVID-19 in January 2022 with mild symptoms; no pulmonary involvement.

After having COVID-19, she still had asthenia, and in March she also had fever and cough with mucous expectoration. Respiratory physical examination: isolated rhonchus at auscultation.

March 2022: chest CAT shows subsegmental linear atelectasis that affect the medial segment of the right middle lobe, apart from thick caves and mild homolateral pleural effusion (Figure 1). Laboratory: high erythrocyte sedimentation rate, negative viral serology. Negative sputum bacilloscopies, positive cultures/GeneXpert® low, without resistance to rifampicin. Patient begins treatment for Category 1 pulmonary TB (unilateral with cave + pleurisy), first phase 2HRZE and second phase 4HR.

DISCUSSION

The presentations of these case reports raise the probable impact of SARS-CoV-2 in the transition from LTBI to disease, excluding the already proven influence of corticosteroids and severe forms of COVID-19. There is increasing evidence to support this idea.

TB affects mainly the lungs when the adaptive immune response, mostly performed by T cells, is altered. With coronavirus infection, there is increased depletion of T cells and a decline in their functional diversity. According to several studies, viruses have been found in T lymphocytes, macrophages and dendritic cells that can also alter their function. So, the coronavirus infection, which activates cellular immunity, results in the depletion of the system that is used for fighting TB1.

The significant influence of the SARS-CoV-2 virus on the immune system that produces severe immunosuppression, activation and progression of existing TB foci can modify the tuberculous infec-

tion due to changes in the nature and intensity of the local cellular immune response. Just like it happens with HIV infections at the AIDS stage, when the reactions of lymphocytes, of epithelioid cells and giant cells become less intense, and inflammation mechanisms and quick dissemination of TB predominate1.

The TB/COVID-19 Global Study Group7 found 71 patients (out of 767) who had been diagnosed with COVID-19 before TB; 48% showed caves, a condition that will likely develop in more than 30 days (time sufficient to develop the disease). Thus, this indirect evidence is against the presumption.

A South African study8 showed that COVID-19 didn't trigger the concomitant activation of CD4+ T cells specific of *M. tuberculosis*; this is against the hypothesis. However, a significant reduction was found in the frequency of these cells in COVID-19 patients compared to pre-pandemic healthy participants with LTBI. This reduction could affect the host's capacity to control the infection with *M. tuberculosis* (latent or new).

There is still a very long way to go, and these questions have been raised. Additional longitudinal studies that observe patients with TB and COVID-19 over time and compare the proportion of those who acquire the TB disease with a control group without COVID-19 can provide a better understanding of their interaction.^{7, 11}

In general, data suggest that TB and COVID-19 are a "cursed duet" and require immediate care7.

Conflict of interest

Authors declare there isn't any conflict of interest in relation to the contents of this article.

REFERENCES

1. Starshinova A, Kudryavtsev I, Malkova A, et al. Molecular and Cellular Mechanisms of *M. tuberculosis* and SARS-CoV-2 Infections - Unexpected Similarities of Pathogenesis and What to Expect from Co-Infection. *Int J Mol Sci.* 2022;23:2235. <https://doi.org/10.3390/ijms23042235>
2. Brian MC. Tuberculosis y COVID-19. *Asociación Argentina de Medicina Respiratoria - AAMR. La Gaceta.* Julio 2020. Disponible en <http://www.aamr.org.ar/lagaceta/tuberculosis-y-covid-19/>
3. Ruhwal M, Hannay E, Sarin S, Kao K, Sen R, Chadha S. Considerations for simultaneous testing of COVID-19 and tuberculosis in high-burden countries. *Lancet Glob Health.* 2022;10:e465-e466. [https://doi.org/10.1016/S2214-109X\(22\)00002-X](https://doi.org/10.1016/S2214-109X(22)00002-X)
4. Comella del Barrio P, De Souza Galvao ML, Prat Aymenrich C, Dominguez J. Impacto de la COVID-19 en el con-

- trol de la tuberculosis. *Arch Bronconeumol.* 2021;57:5-6. <https://doi.org/10.1016/j.arbres.2020.11.016>
5. Viscaa D, Ongc C, Tiberie S, et al. Interacción Tuberculosis y COVID-19: una revisión de efectos biológicos, clínicos y salud pública. *Pulmonology.* 2021; 27: 151-65. <https://doi.org/10.1016/j.pulmoe.2020.12.012>
 6. Rodrigo T, Gullón JA, Tabernero E, et al. Impacto de la pandemia COVID-19 en el Programa Integrado de Investigación en Tuberculosis (PII-TB) de la Sociedad Española de Neumología y Cirugía Torácica (SEPAR). *Enf Emerg.* 2022;21:81-4. Available at http://www.enfermedadesemergentes.com/articulos/a818/4_original_breve_rodrigo.pdf
 7. The TB/COVID-19 Global Study Group. Tuberculosis and COVID-19 co-infection: description of the global cohort. *Eur Respir J.* 2022; 59: 2102538. <https://doi.org/10.1183/13993003.02538-2021>.
 8. Riou C, Bruyn E, Stek C, et al. Relationship of SARS-CoV-2-specific CD4 response to COVID-19 severity and impact of HIV-1 and tuberculosis coinfection. *J Clin Invest.* 2021; 131:e149125. <https://doi.org/10.1172/JCI149125>
 9. Vanzetti C, Salvo C, Kuschner P, Brusca S, Solveyra F, Vilela A. Coinfección Tuberculosis y COVID-19. *ME-DICINA (Buenos Aires).* 2020;80:100-3. Available at https://www.medicinabuenosaires.com/indices-de-2020/volumen-80-ano-2020-s-6-indice/coinfeccion_tuberculosis/
 10. Palmero D, Levi A, Casco N, et al. COVID-19 y tuberculosis en 5 hospitales de la Ciudad de Buenos Aires. *Rev Am Med Resp.* 2020;3:251-4. Available at https://www.ramr.org/articulos/volumen_20_numero_3/comunicacion_breve/comunicacion_breve_covid-19_y_tuberculosis_en_5_hospitales_de_la_ciudad_de_buenos_aires.pdf
 11. Saunders M, Evans C. COVID-19, tuberculosis y pobreza: prevenir una tormenta perfecta. *Eur Resp J.* 2020;56:2001348. <https://doi.org/10.1183/13993003.01348-2020>